

PAPER REF: 4722

## **A METHOD TO AUTOMATICALLY SEGMENT THE INTERNAL EAR STRUCTURES IN CT IMAGES**

**Ana Ferreira<sup>1(\*)</sup>, Francisco Oliveira<sup>1</sup>, Fernanda Gentil<sup>2</sup>, João Manuel R.S. Tavares<sup>1</sup>**

<sup>1</sup>INEGI, Faculty Engineering, University of Porto, Porto, Portugal

<sup>2</sup>Escola Sup. Tecnologias da Saúde do Porto, ORL Clinic, Dr. Eurico Almeida, IDMEC - FEUP, Porto, Portugal

(\*)Email: aiferreira@inegi.up.pt

### **ABSTRACT**

Hereby it is presents a novel methodology to segment the internal structures of the human ear based on image registration. The first step of the methodology concerns the registration of the volumetric image to be segmented with a reference volumetric image previously defined and manually segmented. Then, the geometric transformation found in the registration step is applied to the image to be segmented and consequently, the segmentation of this image is achieved. The methodology was applied on a set of images obtained by X-ray computed tomography revealing very promising results.

**Keywords:** medical imaging, image analysis, registration-based segmentation, computed tomography.

### **INTRODUCTION**

The high prevalence of pathological conditions affecting the ear has become an acute problem of our society. The ear is the most complex organ of the auditory sensory system and responsible for the hearing and balance of the human being [1]. Nowadays, thanks to the advances in imaging technologies, images of high resolution of the ear can be easily obtained. The most widely used imaging modalities in medicine regarding the human ear are the X-ray Computed Tomography (CT) and the Magnetic Resonance Imaging (MRI). However, the visualization of the internal structures of the ear in CT images is difficult due to their small size and the relatively low image resolution of the traditional CT systems. Therefore, automated methods that can assist the analysis of such images are demanded. For example, segmentation techniques [2] can facilitate that 2D analysis and even the 3D reconstruction of the imaged structures [3]. However, the fully automated segmentation of ear CT images is extremely challenging as the structures are very small and located very close to each other. Therefore, we have been developed a segmentation methodology totally automated based on the registration of the volumetric CT image to be segmented with a reference image previously defined and segmented.

The segmentation methodology uses a reference volumetric CT image that represents the human internal ear of a non-pathologic population that is built from a set of volumetric CT images of “normal” subjects that were previously manually segmented. In this process, each image of the reference set is registered with the remainder ones, in order to find at the end the volumetric CT image representative of the population involved. Then, whenever volumetric CT image is to be segmented, the methodology registers this image with the reference image previously found and consequently, the ear structures are automatically segmented by the registration of the correspondent structure in the reference image.

The registration algorithm [4] used in the segmentation methodology can be described by the following main steps: (1) Search for the initial shift correction based on the minimization of the sum of squared difference (SSD) of the voxels intensity within a region of interest (ROI); (2) Apply an optimal rigid transformation, followed by an affine registration to the image to be segmented. (3) A curved registration based on cubic B-splines is applied to the image to be segmented, initially in a coarse mode and then in a fine mode. In the last two steps, the optimal transformation is obtained by maximizing the mutual information (MI) between the image to be segmented and the reference image.

The preliminary results confirm that it is possible to segment successfully the ear structures in volumetric CT images based on the registration of the image to be segmented with a reference image, Figures 1.

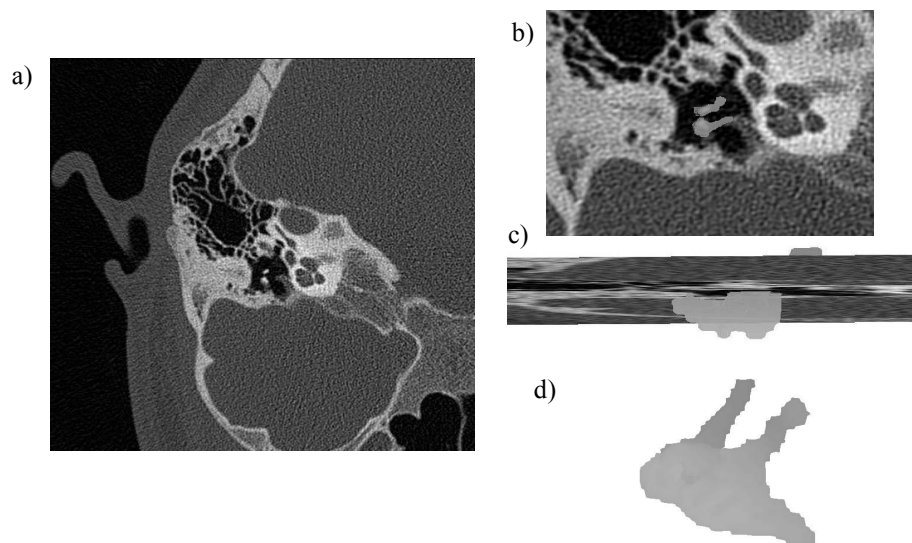


Fig. 1 - a) Original axial CT image slice; b) Image a) zoomed and registered with an inferior view of the ossicles segmented; c) Original coronal CT image slice zoomed and registered with a superior view of the ossicles segmented; d) Ossicles segmented in 3D.

## ACKNOWLEDGMENTS

This work was done in the scope of the projects PTDC/EEACRO/103320/2008 and PTDC/SAU-BEB/104992/2008, supported by FCT, Portugal.

## REFERENCES

- [1]-Moller AR. Hearing: Anatomy, Physiology, and Disorders of the Auditory System, 2<sup>nd</sup> Ed International. San Diego: Academic Press; 2006.
- [2]-Ma Z, Tavares JM, Jorge RN, Mascarenhas T. A review of algorithms for medical image segmentation and their applications to the female pelvic cavity. *Comput Methods Biomech Biomed Engin*, 2010, 13(2), p. 235-246.
- [3]-Ferreira A, Gentil F, Tavares JM. Segmentation algorithms for ear image data towards biomechanical studies. *Comput Methods Biomech Biomed Engin*, DOI: 10.1080/10255842.2012.723700, 2012 (in press).
- [4]-Oliveira FP, Tavares JM. Medical image registration: a review. *Comput Methods Biomech Biomed Engin*, DOI: 10.1080/10255842.2012.670855, 2012 (in press).